

Three-Dimensional Evaluation of Postoperative Swelling After Third Molar Surgery Using 2 Different Cooling Therapy Methods: A Randomized Observer-Blind Prospective Study

Majeed Rana, MD, DDS,*

Nils-Claudius Gellrich, MD, DDS, PhD,†

Alireza Ghassemi, MD, DDS,‡ Marcus Gerressen, MD, DDS,§

Dieter Riediger, MD, DDS, PhD,|| and Ali Modabber, MD, DDS¶

Purpose: In most cases, the removal of third molars leads to a significant degree of tissue trauma, resulting in common postoperative symptoms and signs of pain, facial swelling, dysfunction, and limited mouth opening (trismus). The beneficial effects of cold treatment on postoperative swelling, edema, pain, and inflammation, as well as the reduction in bleeding and hematomas, have been described. The aim of the present study was to compare postoperative cooling therapy using cooling compresses with that using the water-circulating cooling face mask by Hilotherm. We recorded the beneficial effects on postoperative facial swelling, pain, trismus, and neurologic complaints.

Patients and Methods: A total of 30 patients were scheduled to undergo third molar surgery and were divided randomly into 2 groups for treatment with either the Hilotherm or conventional cooling with cooling compresses. Cooling was performed one time for 45 minutes immediately after surgery. Facial swelling was quantified using a 3-dimensional optical scanning technique. The pain and neurologic scores and the degree of mouth opening were observed for each patient.

Results: Patients receiving cooling therapy using Hilotherm demonstrated less facial swelling, less pain, a tendency toward fewer neurologic complaints, and were more satisfied than the patients who had received conventional cooling.

Conclusion: The results of our study have shown that the Hilotherm is more efficient for managing postoperative swelling and pain after the removal of third molars than conventional cooling using compresses.

© 2011 American Association of Oral and Maxillofacial Surgeons

J Oral Maxillofac Surg 69:2092-2098, 2011

In most cases, the removal of third molars will lead to a significant degree of tissue trauma that causes an inflammatory reaction.¹ Thus, the patient develops the common postoperative symptoms and signs of

pain, facial swelling, dysfunction, and limited mouth opening (trismus).² The pain is typically brief and will peak in intensity in the early postoperative period. The facial swelling and trismus will reach their char-

*Department of Oral and Maxillofacial Surgery, Hannover Medical School, Hannover, Germany.

†Department of Oral and Maxillofacial Surgery, Hannover Medical School, Hannover, Germany.

‡Department of Oral, Maxillofacial and Plastic Facial Surgery, University Hospital of the RWTH Aachen, Aachen, Germany.

§Department of Oral, Maxillofacial and Plastic Facial Surgery, University Hospital of the RWTH Aachen, Aachen, Germany.

||Department of Oral, Maxillofacial and Plastic Facial Surgery, University Hospital of the RWTH Aachen, Aachen, Germany.

¶Department of Oral, Maxillofacial and Plastic Facial Surgery, University Hospital of the RWTH Aachen, Aachen, Germany.

Address correspondence and reprint requests to Dr Rana: Department of Oral and Maxillofacial Surgery, Hannover Medical School, Carl-Neuberg-Straße 1, Hannover D-30625, Germany; e-mail: rana.majeed@mh-hannover.de

© 2011 American Association of Oral and Maxillofacial Surgeons

0278-2391/11/6908-0010\$36.00/0

doi:10.1016/j.joms.2010.12.038

acteristic maximum 48 to 72 hours after surgery.³ Those symptoms are a major disadvantage and affect the patient's quality of life. To increase patient satisfaction after third molar surgery, it will be necessary to avoid the inconvenience associated with tooth extraction and minimize the subsequent side effects. One method to reduce the side effects is to prescribe medication such as corticosteroids,⁴ nonsteroidal anti-inflammatory drugs,⁵ a combination of corticosteroids and nonsteroidal anti-inflammatory drugs,⁶ or enzyme preparations such as serratiopeptidase.⁷ In addition, nonmedication methods are available to treat these side effects, including manual lymph drainage,⁸ soft laser,^{9,10} and cryotherapy.¹¹ Cryotherapy has been used since Hippocrates, who described the use of local or systemic application of cold for therapeutic reasons.¹² The beneficial effects of cold treatment on postoperative swelling,¹³⁻¹⁵ the positive consequences on edema, pain, and inflammation,¹⁶⁻¹⁸ and the reduction of bleeding and hematomas have been previously described. Low temperatures lead to a reduction of the activity of inflammatory enzymes.¹⁶ The pain-relieving effect of cold therapy has been well documented. The published oral and maxillofacial surgery scientific evidence and trials showing the positive and negative effects of cold therapy have been insufficient.¹⁹ Different cooling procedures have been studied, including ice packs, gel packs, and cold compresses. Both positive and negative side effects have been reported, including tissue injuries, lymph drainage disturbances, and microcirculation or chilblains. As an alternative to such conventional cooling methods, we studied a procedure that permits continuous cooling using a face mask and a water-circulating cooling device called hilotherapy (Hilotherm, Pleidelsheim, Germany).

The aim of the present study was to examine the effects of hilotherapy, compared with conventional cooling using cold compresses, on swelling, pain, trismus, neurologic complaints, and patient satisfaction after third molar surgery.

Patients and Methods

The local ethics committee at the University of Aachen, Germany approved the study (EK 142/2008). Before the study began, all patients provided written informed consent.

PATIENTS

A total of 30 healthy patients were scheduled for extraction of all wisdom teeth. Only those patients who required an osteotomy of the lower mandible wisdom teeth were divided randomly into 2 treatment groups. Of the 30 patients, 15 were treated with conventional cooling and 15 received continuous

cooling using hilotherapy after extraction of all 4 third molars. At the patient examinations, the observer did not know which therapy had been applied.

COOLING METHODS

Hilotherapy refers to the water-circulating external cooling device Hilotherm Clinic (Hilotherm GmbH). It consists of a preshaped thermoplastic polyurethane mask and the Hilotherm cooling device control unit (Fig 1A,B). The temperature setting is adjustable from +10°C to +30°C and was set to 15°C after surgery.

Conventional cooling was performed using cool compresses. In both groups, the cooling therapy was applied immediately after surgery for a 45-minute period.

STUDY CRITERIA AND PROTOCOL

Only patients with a Pell and Gregory level B and C were included in the present study. The patients who required simple extraction of wisdom teeth of the mandible were not included in the present study. The additional inclusion criteria for participation were misaligned teeth, tooth anomalies, and retained and impacted third molars. Potential participants were excluded from the present study because of missed surgery, foreseeable missed follow-up examination, pregnancy, nursing, drug addiction, recent surgery, and diseases such as heart, metabolism, central nervous system, infectious, circulation, systemic, malignant, and immune system-affecting diseases, as well as blood coagulation disorders and allergic reactions to pharmaceutical agents and antibiotics. All patients were examined and scanned on fixed dates using standardized methods and techniques. Thus, every patient received the same postoperative analgesic (first day, ibuprofen 600 mg 3 times daily; second day, ibuprofen 600 mg 2 times daily; third day, ibuprofen 600 mg 1 time daily; fourth day, ibuprofen 600 mg 1 time daily), and no antibiotic prophylaxis therapy. During the first visit, the physician collected information about previous illnesses and diseases and conducted a standard blood test. The operation took place using general anesthesia.

During the present study, the following parameters were assessed: pain, swelling, neurologic complaints, patient satisfaction, and mouth opening.

POSTOPERATIVE PAIN ANALYSIS

The postoperative pain analysis was conducted with the help of a visual analog scale on a daily basis from the 2nd to the 10th day, in which the patients should rate their pain on a score from 0 to 10, with 0 describing a situation without pain and 10 denoting a maximal intensity of pain.

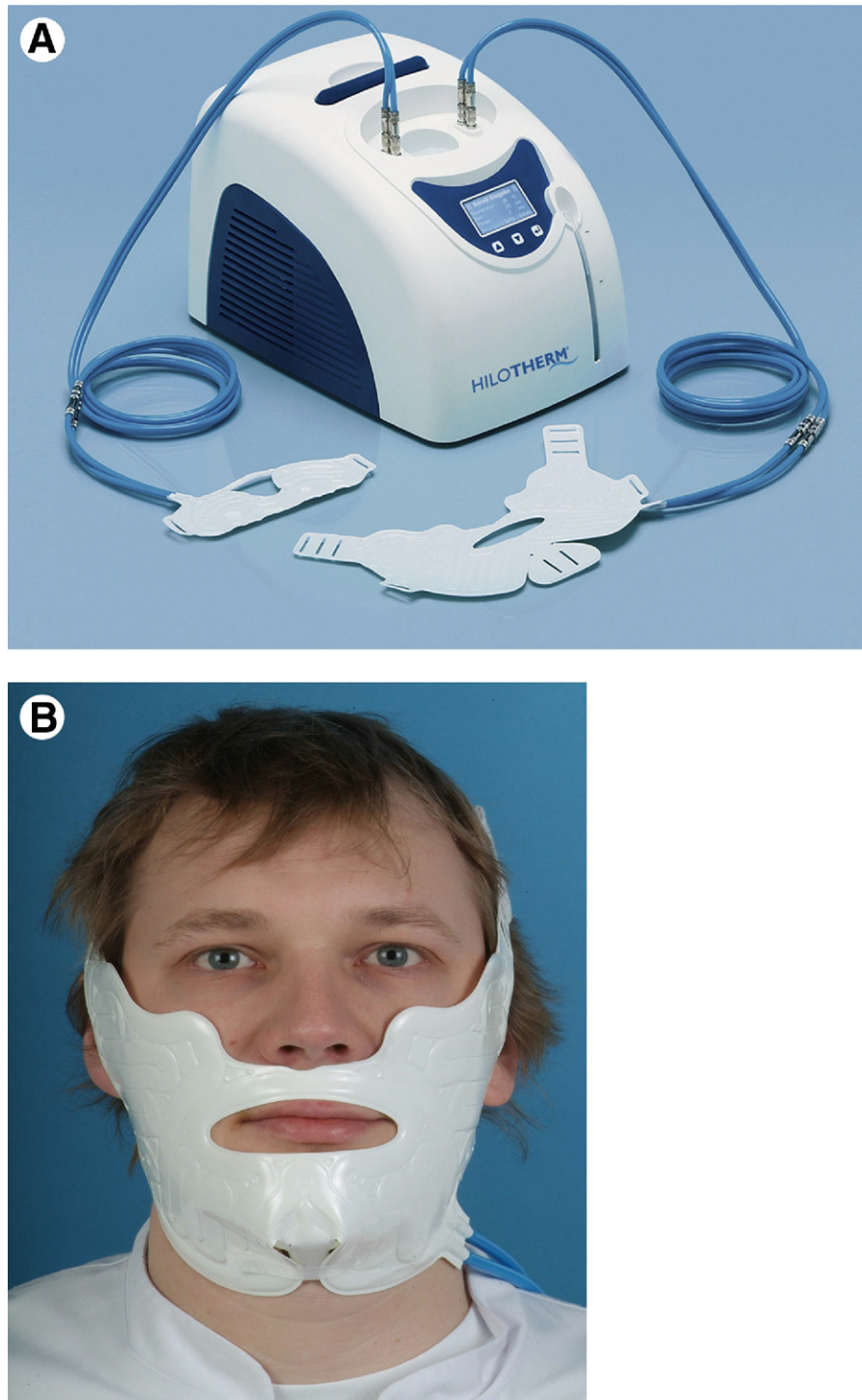


FIGURE 1. A, Hilotherm device connected with 2 masks. A maximum of 2 masks can be connected to 1 Hilotherm device. Temperature can be adjusted from 10° to 30°C. B, Front view of patient wearing mask.

Rana et al. Cooling Therapy After Third Molar Surgery. J Oral Maxillofac Surg 2011.

FACIAL SWELLING MEASUREMENT

The present study used a 3-dimensional (3D) optical scanner (FaceScan3D; 3D-Shape GmbH, Erlangen, Germany) to measure facial swelling in volume. The 3D optical scanner consists of an optical range sensor,

2 digital cameras, mirror construction, and a commercial personal computer. The sensor is based on a phase-measuring triangulation method.²⁰ Special safety precautions are not needed for the patient, because the advantage of this optical sensor is its

contactless data acquisition accompanied by its high accuracy in the z-direction with 200 μm and a short measurement time of 430 ms. The mirror construction permits the capture of greater than 180° of the patient's face. The computer program Slim3D (3D-Shape) automatically triangulates, merges, and post-processes the data.²¹ The final output is a triangulated polygon mesh that is visualized as a synthetically shaded or wire mesh representation.²² For the volume calculation, all patients were photographed using a standard technique for frontal views of the face. Adjustment occurred on the Frankfurt horizontal line, parallel to the floor. Patients sat on a self-adjustable stool and were asked to look into a mirror with standard horizontal and vertical lines simulating a red cross marked on it. The horizontal line was adjusted to subnasale and the midline of the face was aligned to the vertical line. The patients were instructed to swallow hard and to keep their jaws in a relaxed position for the scan. 3D optical scans were recorded at 5 points: before surgery (T0), directly after surgery (T1), and on the 2nd (T2), 10th (T3), and 28th (T4) postoperative day. The reference 3D model for each patient was the scan from T0. The resulting difference in volume was calculated as described swelling, using the computer software Comparison (3D-Shape).

NEUROLOGIC ANALYSIS

The neurologic analysis was performed bilaterally. It was used to evaluate nerve dysfunctions. The skin of the infraorbital, mental region, and upper and lower lip were checked using a cotton test for touch sensation, a pinprick test using a needle for sharp pain, and a blunt instrument for testing pressure. Additionally, a 2-point discrimination test was executed on these regions. The same procedure was accomplished for the lower lip and the mental nerve skin region. The results were recorded on a score with a range of 0 to 13, with 13 the worst neurologic score. The neurologic score was assessed at 3 points: before surgery (T0) and on the 2nd (T1) and the 28th (T2) postoperative day.

PATIENT SATISFACTION

Each patient was asked to complete a questionnaire on the 10th postoperative day. The question was how they rated their satisfaction and convenience of the applied postoperative cooling therapy on a subjective basis. The grading scale ranged from 1 to 4, with 1 indicating very satisfied and 4, not satisfied.

MOUTH OPENING MEASUREMENT

Trismus was calculated using the interincisal mouth opening and was measured with a caliper. The result was recorded in millimeters and observed at 5 points: before surgery (T0), directly after surgery (T1), and

Table 1. BASELINE PATIENT CHARACTERISTICS

Characteristic	Hilotherm	Conventional	P Value
Female gender/ total (%)	5/17 (29)	7/15 (47)	.5
Age (yr)	23.5 \pm 4.7	24.7 \pm 5.5	.499
Body mass index (kg/m ²)	23.6 \pm 3.8	23.9 \pm 3.6	.281
Operation duration (min)	70.2 \pm 20.8	67.6 \pm 19	.784

Data presented as numbers of patients, with percentages in parentheses, or mean \pm standard deviation.

Rana et al. Cooling Therapy After Third Molar Surgery. J Oral Maxillofac Surg 2011.

on the 2nd (T2), 10th (T3), and 28th (T4) postoperative day.

STATISTICAL ANALYSIS

All data are expressed as the mean value \pm standard error of the mean. For repeating measures, 1-way analysis of variance with post hoc Bonferroni's test for multiple comparisons of the mean was applied. Because the observed parameters consisted of dichotomous variables, a chi-square test and a Wilcoxon test were conducted to detect differences between conventional cooling and hilotherapy. To check for statistical significance of quantitative variables, the Student *t* test was used, with $P < .05$ considered significant. The statistical analysis was conducted using the Statistical Package for Social Sciences for Windows, version 14.0 (SPSS, Chicago, IL).

Results

BASELINE CHARACTERISTICS

A total of 30 patients were randomly enrolled in the present study. After third molar surgery, 15 patients were assigned to conventional cooling therapy and 15 patients were treated with hilotherapy. The clinical and demographic characteristics of the 30 patients are listed in Table 1. No statistically significant differences were noted regarding gender, age, body mass index, or surgery duration in either group.

POSTOPERATIVE SWELLING

Swelling was measured in terms of volume in milliliters. On the second day after surgery, a statistically significant downregulation of swelling could be achieved with the Hilotherm cooling device compared with conventional cooling therapy (Hilotherm 72.2 \pm 14.9 mL, conventional 96.6 \pm 20.9 mL, $P = .005$; Fig 2). This tendency was maintained on the 10th postoperative day (Hilotherm 23.3 \pm 6.1 mL, conventional 46.7 \pm 12.7 mL, $P < .001$). After 28

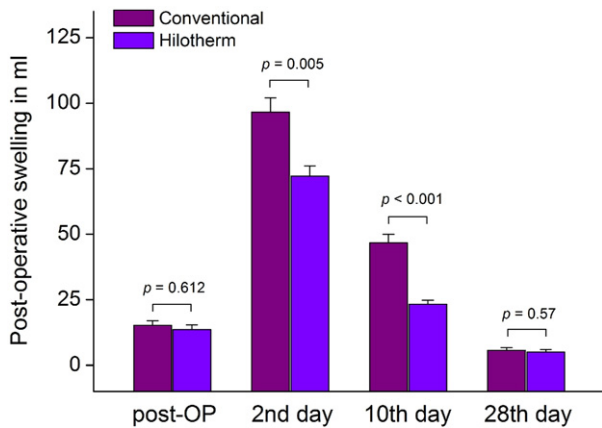


FIGURE 2. Amount of swelling in milliliters of both groups at different points. At second postoperative day, significant down-regulation of swelling achieved by cooling with Hilotherm compared with conventional cooling. Trend maintained at 10th postoperative day. After 28 days, no differences in swelling found between groups.

Rana et al. *Cooling Therapy After Third Molar Surgery. J Oral Maxillofac Surg* 2011.

days, no statistically significant differences with respect to swelling could be documented in either group (Hilotherm 5.1 ± 3.4 mL, conventional 5.8 ± 3.7 mL, $P = .57$). Maximal swelling was noticed at the second day after surgery with 72.2 ± 14.9 mL using hilotherapy and 96.6 ± 20.9 mL with conventional cooling.

POSTOPERATIVE PAIN

Pain was calculated using a visual analog scale from subjective analysis ranging from 0 to 10. At the second and third postoperative day, a significant down-regulated pain score was assessed by hilotherapy compared with conventional cooling (second day, Hilotherm 3.4 ± 1.5 and conventional 4.8 ± 1.6 , $P < .05$; third day, Hilotherm 2.9 ± 1.1 and conventional 3.7 ± 1.2 , $P < .05$; Fig 3). Although not statistically significant, at the fourth postoperative day, we could achieve lower pain scores compared with conventional cooling (Hilotherm 1.7 ± 0.7 and conventional 2.1 ± 0.8 , $P = .06$). At the 28th postoperative day, no differences were found in the pain score between the 2 groups (Hilotherm 0.3 ± 0.1 and conventional 0.3 ± 0.1 , $P = .67$).

POSTOPERATIVE NEUROLOGIC SCORE

No statistically significant differences were found between the 2 groups concerning the neurologic score at 2 and 10 days after third molar extraction (second day, Hilotherm 1.2 ± 0.6 and conventional 1.1 ± 0.6 , $P = .8$; 10th day, Hilotherm 0.07 ± 0.3 and conventional 0.1 ± 0.4 , $P = .6$; Fig 4). However, a highly significant decrease in the neurologic score could be observed after 10 days compared with the

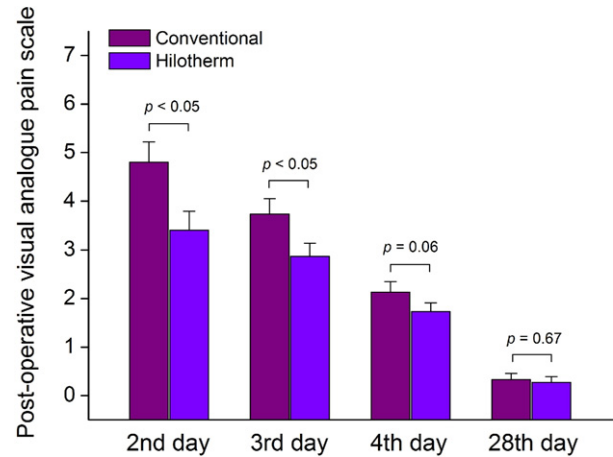


FIGURE 3. Pain calculated using visual analog scale from subjective analysis ranging from 0 to 10. Significant increase in pain reported in conventional group compared with Hilotherm group at second and third postoperative days. Pain intensity remained significantly unchanged during 4th and 28th postoperative day in both groups.

Rana et al. *Cooling Therapy After Third Molar Surgery. J Oral Maxillofac Surg* 2011.

results at the 2nd postoperative day in the 2 groups (Hilotherm, 2nd day 1.2 ± 0.6 vs 10th day 0.07 ± 0.3 , $P < .001$; conventional, second day 1.1 ± 0.6 vs 10th day 0.1 ± 0.4 , $P < .001$).

TRISMUS

Postoperatively and at the second postoperative day, the mouth opening was significantly greater in the Hilotherapy group than in the conventional cooling group (postoperatively, Hilotherm 22.8 ± 0.7 and conventional 17.1 ± 0.7 , $P = .01$; second day, Hilotherm 25.1 ± 2.4 and conventional 22.0 ± 1.9 , $P =$

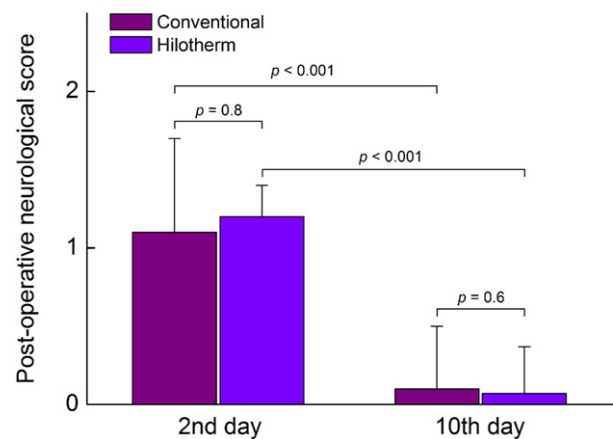


FIGURE 4. No changes found concerning neurologic score at 2nd and 10th postoperative days in both groups. However, highly significant decrease in neurologic score observed at 10th day compared with 2nd postoperative day in both groups.

Rana et al. *Cooling Therapy After Third Molar Surgery. J Oral Maxillofac Surg* 2011.

FIGURE 5. Preoperative mouth opening values did not differ significantly in either group. Postoperatively, significant reduction in mouth opening seen in both groups. Reduction in mouth opening significantly lower in Hilotherm group than in conventional group. At second postoperative day, significant increase in mouth opening seen in both groups compared with immediately postoperatively. Reduction in mouth opening remained significantly lower in Hilotherm group than in conventional group at second postoperative day. At 28 days postoperatively, mouth opening had increased to preoperative values and no differences were observed between either group or compared with baseline.

Rana et al. Cooling Therapy After Third Molar Surgery. J Oral Maxillofac Surg 2011.

.002; Fig 5). The mouth opening returned to normal values 28 days after surgery without statistically significant differences between the 2 groups.

PATIENT SATISFACTION

Patient satisfaction was assessed at the second day after surgery. A statistically significant difference was found between the Hilotherapy and conventional cooling groups (Hilotherm 1.9 ± 0.2 and conventional 3.1 ± 0.3 , $P = .003$) (Fig 6).

Discussion

The results of the present study have demonstrated that continuous cooling with the Hilotherapy devices reduces postoperative swelling, pain, and trismus after third molar surgery compared with conventional cooling using cold packs. Furthermore, patient satisfaction with Hilotherapy was greater than that with conventional cooling. However, the postoperative neurologic score was unchanged in both groups.

It has been shown that the healing process and the possible complaints after removal of third molars can be influenced by various factors, including surgeon experience, patient age and gender, and the need for tooth sectioning or bone removal.^{1,23-26} Another variable that can influence the degree of facial swelling is the operating time, which again is related to surgical difficulties in extraction.²⁷ Because the operating

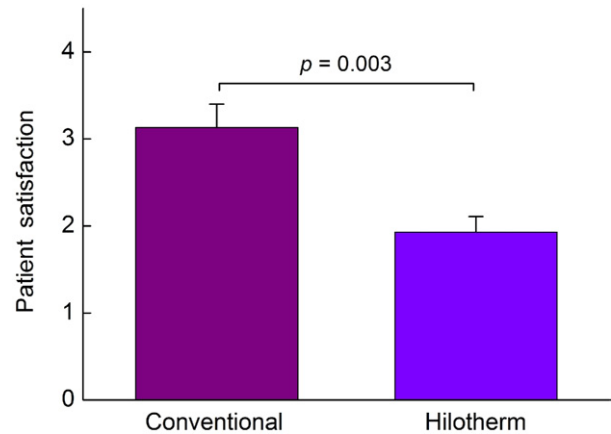


FIGURE 6. Overall satisfaction significantly lower for patients receiving conventional therapy than for patients receiving Hilotherm therapy. Grading scale ranged from 1 to 4, with 1 indicating very satisfied and 4, not satisfied.

Rana et al. Cooling Therapy After Third Molar Surgery. J Oral Maxillofac Surg 2011.

time was not significantly different in the 2 groups, this factor did not have an effect on the results.

Although cryotherapy is a relatively safe method to treat complications after oral or maxillofacial surgery, cold therapy should be used with caution. Above all, very young or very old patients can react with intolerance to external cooling.²⁸ However, because the region that is affected by swelling after third molar surgery has a superior blood supply, the probability of these contraindications is very low after oral and maxillofacial surgery.¹⁹

The biologic vascular, neural, metabolic, and muscular effects of cooling therapy are known. Cryotherapy decelerates the cell metabolism, because, according to van't Hoff's law, it slows down the biochemical reactions. Regarding the vascular effects, cold therapy constricts the blood vessels. The intensity of vasoconstriction reaches the greatest value at a temperature of 15°C. Furthermore, a decrease in body temperature slows down peripheral nerve conduction. For temperatures less than 15°C, nerve conduction is completely disabled, and vasoconstriction becomes vasodilation. These biologic effects influence the postoperative symptoms. Also, the antiedema effect is caused by vasoconstriction, and the pain-reducing effect of the cold therapy is related to the blocking of nerve endings. This blocking decelerates nerve conduction and, consequently, inflammation. Ice packs or similar conventional cooling methods use a temperature of about 0°C. Such a low temperature constrains lymph drainage and cell metabolism.²⁹ The effects of a treatment with too low a temperature have been previously mentioned. The inference is that a system is needed that maintains the desired temperature for a fixed period. To fulfill this requirement, the present study used the cool-

ing device Hilotherm Clinic (Hilotherm GmbH). Compared with cool compresses, it is not necessary to change ice packs regularly. The Hilotherm represents a simple, easy-to-use, and cost-effective treatment alternative to conventional cooling.

References

1. Capuzzi P, Montebugnoli L, Vaccaro MA: Extraction of impacted third molars. A longitudinal prospective study on factors that affect postoperative recovery. *Oral Surg Oral Med Oral Pathol* 77:341, 1994
2. Miloro M: Peterson's Principles of Oral and Maxillofacial Surgery (ed 2). Canada, BC Decker, 2004
3. Seymore R, Meechan JG, Blair GS: An investigation into postoperative pain after third molar surgery under local analgesia. *Br J Oral Maxillofac Surg* 23:410, 1985
4. Grossi GB, Maiorana C, Garramone RA, et al: Effect of submucosal injection of dexamethasone on postoperative discomfort after third molar surgery: A prospective study. *J Oral Maxillofac Surg* 65:2218, 2007
5. Benetello V, Sakamoto FC, Giglio FP, et al: The selective and non-selective cyclooxygenase inhibitors valdecoxib and piroxicam induce the same postoperative analgesia and control of trismus and swelling after lower third molar removal. *Braz J Med Biol Res* 40:1133, 2007
6. Bamgbose BO, Akinwande JA, Adeyemo WL, et al: Effects of co-administered dexamethasone and diclofenac potassium on pain, swelling and trismus following third molar surgery. *Head Face Med* 1:11, 2005
7. Al-Khateeb TH, Nusair Y: Effect of the proteolytic enzyme serrapeptase on swelling, pain and trismus after surgical extraction of mandibular third molars. *Int J Oral Maxillofac Surg* 37:264, 2008
8. Szolnoky G, Szendi-Horváth K, Seres L, et al: Manual lymph drainage efficiently reduces postoperative facial swelling and discomfort after removal of impacted third molars. *Lymphology* 40:138, 2007
9. Braams JW, Stegenga B, Raghoobar GM, et al: Treatment with soft laser. The effect on complaints after the removal of wisdom teeth in the mandible. *Ned Tijdschr Tandheelkd* 101:100, 1994
10. Røynesdal AK, Björnland T, Barkvoll P, et al: The effect of soft-laser application on postoperative pain and swelling: A double-blind, crossover study. *Int J Oral Maxillofac Surg* 22:242, 1993
11. Laureano-Filho JR, de Oliveira e Silva ED, Batista CI, et al: The influence of cryotherapy on reduction of swelling, pain and trismus after third-molar extraction: A preliminary study. *J Am Dent Assoc* 136:774, 2005
12. Stangel L: The value of cryotherapy and thermotherapy in the relief of pain. *Physiotherapy (Canada)* 27:135, 1975
13. McMaster WC, Liddle S: Cryotherapy influence on posttraumatic limb edema. *Clin Orthop* 150:283, 1980
14. Swanson AB, Livengood LC, Sattel AB: Local hypothermia to prolong safe tourniquet time. *Clin Orthop* 264:200, 1991
15. Wright JG, Fox D, Kerr JC, et al: Rate of reperfusion blood flow modulates reperfusion injury in skeletal muscle. *J Surg Res* 44:754, 1988
16. Abramson DI, Chu LS, Tuck S, et al: Effect of tissue temperature and blood flow on motor nerve conduction velocity. *JAMA* 198:1082, 1996
17. Fruhstorfer H: Nozizeption und Postoperativer Schmerz: Lehmann KA: *Der Postoperative Schmerz* (ed 1). Berlin, Springer, 1990, pp 21-30
18. Schaubel HJ: The local use of ice after orthopaedic procedures. *Am J Surg* 72:711, 1946
19. Van der Westhuijzen AJ, Becker PJ, Morkel J, et al: A randomized observer blind comparison of bilateral facial ice pack therapy with no ice therapy following third molar surgery. *Int J Oral Maxillofac Surg* 34:281, 2005
20. Gruber M, Häusler G: Simple, robust and accurate phase-measuring triangulation. *Optik* 89:118, 1992
21. Laboureux X, Häusler G: Localization and registration of three-dimensional objects in space—Where are the limits? *Appl Opt* 40:5206, 2001
22. Hartmann J, Meyer-Marcotty P, Benz M, et al: Reliability of a method for computing facial symmetry plane and degree of asymmetry based on 3D-data. *J Orofac Orthop* 68:477, 2007
23. Monaco G, Staffolani C, Gatto MR, et al: Antibiotic therapy in impacted third molar surgery. *Eur J Oral Sci* 107:437, 1999
24. Haug RH, Perrott DH, Gonzales ML, et al: The American Association of Oral and Maxillofacial Surgeons Age-related third molar study. *J Oral Maxillofac Surg* 63:1106, 2005
25. Piecuch JF, Arzadon J, Lieblich SE: Prophylactic antibiotics for third molar Surgery: A supportive opinion. *J Oral Maxillofac Surg* 53:53, 1995
26. Poeschl PW, Eckel D, Poeschl E: Postoperative prophylactic antibiotic treatment in third molar surgery—A necessity? *J Oral Maxillofac Surg* 62:3, 2004
27. Yuasa H, Sugiura M: Clinical postoperative findings after removal of impacted mandibular third molars: Prediction of postoperative facial swelling and pain based on preoperative variables. *Br J Oral Maxillofac Surg* 42:209, 2004
28. Cameron MH: *Physical agents in rehabilitation, in Research to Practice*. Philadelphia, PA, WB Saunders, 1999, pp 129-148
29. Guyton AC: *Medical Physiology*. Philadelphia, PA, WB Saunders, 1991